Invasive Physiotherapy and Musculoskeletal Medicine

eISSN: 3101-0105 invasivephysiotherapy.com

doi: 10.63360/ipmm.v2.e52

Clinical Case

Needle–Surface Electroacupuncture for Metatarsalgia and Plantar Fasciitis: A Clinical Case Report

Nicholas Ghines[1] 0009-0007-1340-5292

Katerina Simati[1,2] 0009-0000-0745-5241

Giorgos Tzigkounakis[1,3] 0009-0005-3823-1861

[1] Department of Research, Health and Resilience Institute, Athens, Greece.

[2] Department of Physiotherapy, Mediterranean College, Athens, Greece.

[3] Department of Physiotherapy, University of Nicosia, Nicosia, Cyprus.

ABSTRACT

Introduction: Metatarsalgia and plantar fasciitis are common causes of plantar foot pain that can substantially impair function and quality of life. While conservative management is recommended for both conditions, evidence supporting electroacupuncture (EA), particularly for metatarsalgia, remains limited. This case report describes a modified EA technique combining acupuncture needles with adhesive surface electrodes to improve treatment tolerability while maintaining electrical stimulation of the symptomatic region.

Case presentation: A 55-year-old woman presented with persistent bilateral plantar foot pain, clinically diagnosed as left metatarsalgia and right plantar fasciitis. Previous treatment with extracorporeal shockwave therapy and transfer of energy capacitive and resistive (TECAR) therapy failed to improve symptoms. A course of electroacupuncture was initiated. Following poor tolerance of plantar needling, the protocol was modified by replacing plantar needle electrodes with adhesive surface electrodes and changing stimulation from alternating 2/100 Hz to continuous 100 Hz.

Results: By the final session, pain on the Numeric Rating Scale (NRS) had fallen from 8/10 to 1/10 (left) and 7/10 to 3/10 (right), with immediate post-treatment pain completely abolished in both feet. Patient-Specific Functional Scale scores improved from 2–3/10 at baseline to 8/10 after treatment and were maintained at three-week follow-up. The left foot remained pain-free at follow-up, whereas the right foot demonstrated mild activity-related pain associated with occupational loading.

Conclusions: This case suggests that needle–surface EA may represent a feasible and well-tolerated clinical adaptation for patients with plantar foot pain who poorly tolerate repeated plantar needling. Although treatment efficacy cannot be inferred from a single case, the technique warrants further investigation in controlled clinical studies.

Keywords: Electroacupuncture; Metatarsalgia; Fasciitis, Plantar; Case Reports; Electric Stimulation Therapy; Physical Therapy Modalities; Chronic Pain.

4.0 BY-NC-SA

Correspondence: info@healthandresilience.org

1. Introduction

Metatarsalgia is a forefoot pain syndrome characterised by pain beneath the lesser metatarsal heads, most commonly the second to fourth metatarsals, resulting from mechanical overload and increased plantar pressure during standing, walking, or weight-bearing. Causes are classified as primary, secondary, or iatrogenic. It occurs predominantly in middle-aged and older adults and is more common in women, partly owing to forefoot deformities and footwear-related loading[1,2]. Biomechanically, metatarsalgia is associated with central metatarsal pressure, altered load transfer, forefoot deformity, hallux valgus or rigidus, pes cavus, fat-pad changes, and gastrocnemius tightness or equinus[1]. Current evidence supports conservative management, especially custom orthoses, metatarsal support, footwear modification, and plantar-pressure redistribution[3].

Plantar fasciitis is the most common cause of plantar heel pain and is characterised by medial plantar heel pain and tenderness over the medial calcaneal tubercle, with symptoms typically most noticeable during the first weight-bearing steps after periods of rest[4]. Although traditionally regarded as an inflammatory condition, plantar fasciitis is now recognised to exist along a pathological spectrum that includes both inflammatory and degenerative characteristics. The differential diagnosis of plantar heel pain includes heel fat pad syndrome, heel spur syndrome, nerve irritation, and calcaneal stress fracture. Plantar heel pain is most prevalent in adults aged 50–65 years and is independently associated with female sex, increasing body mass index, hypertension, kidney stone history, and osteoporosis[5].

Common treatments for both conditions include exercise, shockwave therapy (SWT), High- and Low-Level Laser Therapy, radiofrequency, orthotics, footwear modification, and patient education[1,4,6]. Treatment evidence for metatarsalgia is more limited than for plantar fasciitis, particularly for invasive physiotherapy approaches such as dry needling (DN) and electroacupuncture (EA). Nevertheless, experimental studies have demonstrated several analgesic mechanisms of EA, providing a biologically plausible rationale for its use in musculoskeletal pain.

EA may contribute to analgesia by activating endogenous opioid pathways. It can be delivered using different waveforms (continuous, sparse-dense, and intermittent), which differ in how low- and high-frequency pulses are combined[7]. Analgesic effects appear to be influenced by frequency and waveform. Low-frequency stimulation is mainly associated with enkephalin, β-endorphin, and endomorphin systems, whereas high-frequency stimulation is more closely related to dynorphin-mediated mechanisms[7,8]. Sparse-dense stimulation may recruit multiple endogenous opioid peptide systems by alternating low- and high-frequency inputs. However, the optimal waveform is not standardized, and different frequency patterns may produce different analgesic duration and intensity[7,9,10]. Experimental evidence also suggests that EA may exert anti-inflammatory effects. In a mouse model of neuropathic pain, Fang et al. demonstrated frequency-dependent analgesic mechanisms, with 2 Hz stimulation increasing enkephalin and β-endorphin expression, whereas 100 Hz preferentially increased dynorphin expression. Both frequencies also reduced spinal concentrations of the pro-inflammatory cytokines IL-1β and TNF-α, suggesting that EA modulates both endogenous opioid and neuroinflammatory pathways[11,12] .

During EA, inserted needles function as electrodes embedded within conductive biological tissues, generating an electric field rather than a simple point-to-point current pathway between needle pairs. The resulting three-dimensional electric field depends on tissue electrical properties, needle geometry, insertion depth, electrode configuration, and stimulation intensity[13–15]. Current density is greatest near the needle tip and decreases rapidly with distance from the needle, producing a localized deeper field, whereas surface-electrode current is broader and concentrated near the skin surface[14–16].

Needle insertion into the plantar surface is often painful and may reduce treatment acceptability. This case report describes a modified EA technique combining conventional acupuncture needles with adhesive patch electrodes to minimise plantar needle insertion while maintaining electrical stimulation of the symptomatic region.

2. Description of the clinical case

This case report was prepared in accordance with the PhyCARE reporting guidelines for physiotherapy case reports[17]. A completed PhyCARE checklist is provided as Supplementary Material.

2.1 Patient information

The patient was a 55-year-old woman (BMI 21.2 kg/m^2) who had worked as a sales representative for 24 years, standing for >50 hours/week. The patient was postmenopausal, had no relevant medical history, was a non-smoker, and reported low levels of physical activity. Her pain first appeared in the left foot approximately five months before the initial assessment. Two months later, she developed pain in the right foot. The pain was initially tolerable but gradually worsened.

Following physiotherapeutic assessment, plantar fasciitis was suspected, and the patient received SWT once weekly for four consecutive weeks. The treatment parameters were not available.

Despite completing the four-session protocol, the patient reported no clinical improvement. Subsequent orthopaedic assessment resulted in a clinical diagnosis of left metatarsalgia and right plantar fasciitis. The orthopaedic physician recommended therapeutic exercise and TECAR (Transfer of Energy Capacitive and Resistive) therapy instead of further SWT. No non-steroidal anti-inflammatory drugs (NSAIDs) were prescribed. The patient subsequently completed three TECAR sessions at 3–4-day intervals, with no improvement in pain, which remained at 8/10 on the Numeric Rating Scale (NRS). During the final session, EA was proposed as an alternative pain management strategy. At this stage, the patient's condition met the International Association for the Study of Pain (IASP) and ICD-11 criteria for chronic primary pain[18].

2.2 Clinical Findings

The main clinical finding was persistent bilateral plantar foot pain with localized tenderness on manual palpation. In the left foot, pain was located at the plantar metatarsal region, mainly around the hallux, second toe, and medial forefoot. In the right foot, pain was localized to the

plantar heel region, extending along the plantar aponeurosis and toward the lateral side of the foot.

At baseline, pain intensity was 8/10 on the NRS in the left foot and 7/10 in the right foot. Symptoms were aggravated by prolonged standing and daily activity.

2.3 Timeline

A chronological summary of the patient's clinical course and interventions before EA is presented in Table 1.

Table 1. Timeline of key clinical events and prior interventions

Time point	Key clinical event
5 months before initial assessment	Left plantar forefoot pain began.
3 months before initial assessment	Right plantar heel pain developed.
Initial physiotherapy assessment	Findings considered compatible with plantar fasciitis.
Following assessment	Four weekly SWT sessions completed without clinical improvement.
Orthopaedic assessment	Left metatarsalgia and right plantar fasciitis diagnosed clinically; no imaging obtained.
After orthopaedic assessment	Three TECAR sessions completed at 3–4-day intervals without measurable NRS improvement.
Baseline before electroacupuncture	NRS 8/10 left foot and 7/10 right foot; tenderness reproduced by manual palpation.

Abbreviations: SWT, shockwave therapy; TECAR, Transfer of Energy Capacitive and Resistive; NRS, Numeric Rating Scale.

2.4 Diagnostic assessment

The orthopaedic physician clinically diagnosed left metatarsalgia and right plantar fasciitis based on pain intensity (NRS), functional limitation, and palpation findings. No imaging examination was obtained. Therefore, both diagnoses were based solely on clinical assessment and the physician's clinical judgement. This represents a diagnostic limitation, as imaging could have helped exclude other causes of plantar foot pain, including stress fracture, nerve entrapment, fat-pad pathology, Morton's neuroma, or structural forefoot abnormalities.

2.5 Therapeutic intervention

Treatment was delivered by a physiotherapist with three years' experience in electroacupuncture and DN, in an outpatient physiotherapy setting in Athens, Greece.

Prior to needle insertion, the treatment areas were disinfected with isopropyl alcohol using sterile gauze. The procedure was performed using sterile gloves. The initial EA interventions were performed using sterile, single-use, copper-handle needles (0.25 × 30 mm; EAKU 5CB, Synergi Europe Ltd., Chipping Norton, Oxfordshire, UK). Electrical stimulation was delivered using the 8c Pro electroacupuncture device (Pantheon Research Inc., Fair Oaks, CA, USA), which has a reported frequency accuracy of 99.94%[19]. Each intervention lasted 30 minutes.

The therapist initially intended to insert two to three plantar needles for conventional needle-to-needle EA. Although the patient had previously tolerated acupuncture and DN for other conditions, insertion of the second plantar needle caused marked discomfort, prompting her to decline further needling and electrical stimulation at this site and request removal of the

needles. They were removed without electrical stimulation, and the 30-minute treatment proceeded entirely using a needle–surface configuration (NSC).

A single needle was retained at LR3 (Taichong), on the dorsum of the foot between the first and second metatarsal bones, located according to the WHO Standard Acupuncture Point Locations[20], while an adhesive patch electrode (50 × 90 mm; MyoTrode Plus, Globus Inc., Fallbrook, CA, USA) was placed over the symptomatic plantar region of each foot (Figure 1). This setup delivered one EA channel per foot, pairing the LR3 needle with the plantar pad, and was used for all eight sessions.

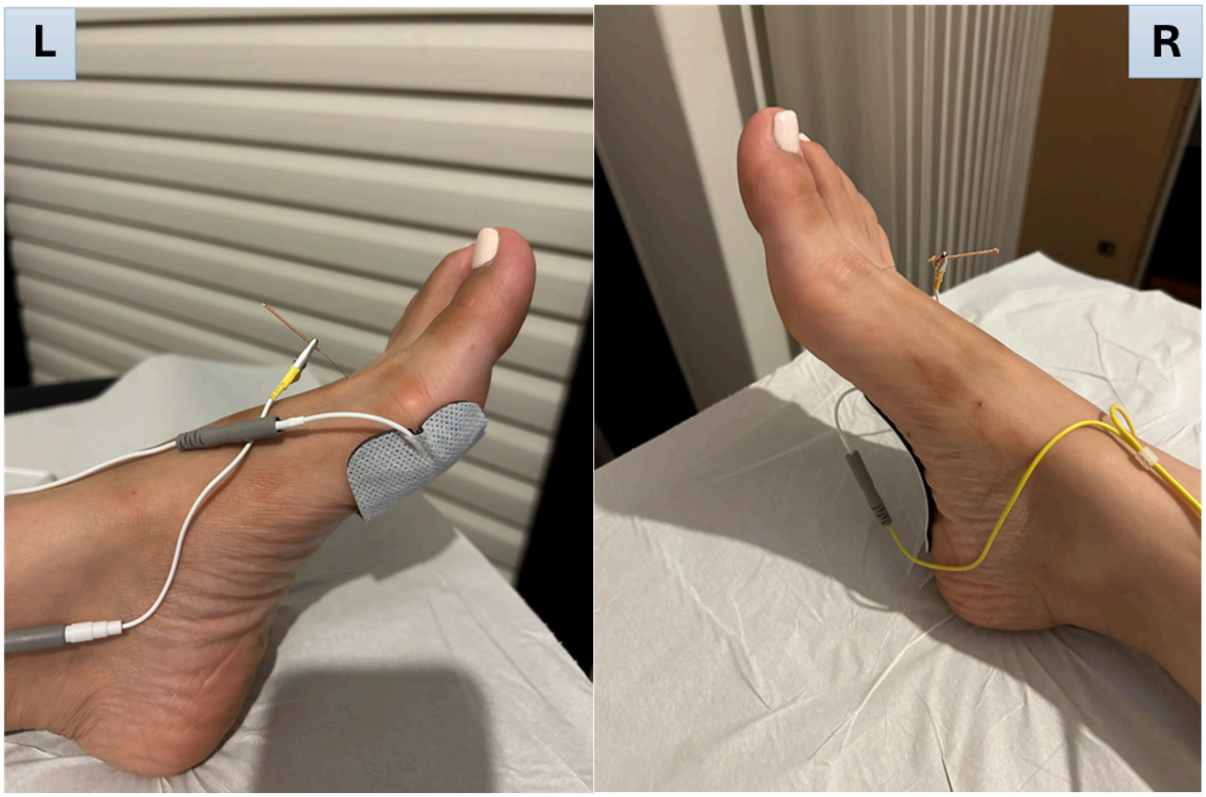

Figure 1. Needle–surface electrode configuration on the plantar region.

The selection of LR3 was based on its anatomical proximity to the symptomatic region and its suitability as a better-tolerated dorsal needle electrode, allowing regional electrical stimulation to be maintained without further plantar needling.

Needle depth at LR3 was approximately 0.5–1 cun (≈1–1.5 cm in this patient). Treatments were twice weekly, 3–4 days apart. The first session used alternating 2/100 Hz stimulation, selected because sparse–dense stimulation may recruit multiple endogenous opioid peptide systems and provide broader opioid-mediated analgesia[7,8]. From the second session onward, stimulation was changed to continuous 100 Hz. The device delivered a symmetrical biphasic modified sine waveform with a pulse duration of 0.4 ms and an output range of 0–15 mA per channel[21]. As the delivered current was not displayed numerically by the device, intensity was progressively increased and individually titrated to the patient's maximum comfortable level.

Outcomes were pain intensity (NRS, 0–10) and function (Patient-Specific Functional Scale [PSFS], 0–10)[22]. NRS was recorded immediately before and after each of the eight sessions and at a 3-week follow-up. PSFS was recorded at baseline, after the final session, and at follow-up

(Tables 2, 3). A 10-session course was planned. The patient stopped after the eighth session owing to marked improvement and was followed up thereafter.

3. Results

Overall, the patient demonstrated a marked reduction in pain across the eight EA sessions, with pain improving from the first session onward.

Following the first treatment session, pain intensity decreased from 8/10 to 3/10 in the left foot (ΔNRS = −5 points; 62.5% reduction) and from 7/10 to 2/10 in the right foot (ΔNRS = −5 points; 71.4% reduction). Both improvements exceeded the threshold for a clinically significant change in pain reported for patients with high baseline VAS scores[23].

At the beginning of the second session, the patient reported that the treatment had provided greater symptom relief than any previous intervention. Baseline pain remained lower than at the initial assessment, and post-treatment pain reduction was comparable to that achieved after the first session. During the third session, the patient reported improved pain control throughout the day, while immediate post-treatment pain reduction remained consistent with that observed after the initial sessions (Table 2). Pain continued to improve throughout the remaining treatment sessions (Table 2). Other than the initial plantar-needling discomfort, which resolved once the surface electrode was introduced, no adverse effects were reported during treatment.

The patient elected to stop after the eighth of ten planned sessions as symptoms had largely resolved.

Table 2. Pain intensity (NRS) before and after each electroacupuncture session and at 3-week follow-up

Session	Left foot Pre	Left foot Post	Right foot Pre	Right foot Post
1	8/10	3/10	7/10	2/10
2	6/10	3/10	7/10	2/10
3	5/10	1/10	5/10	2/10
4	3/10	0/10	4/10	2/10
5	2/10	0/10	4/10	1/10
6	2/10	0/10	4/10	0/10
7	2/10	0/10	3/10	0/10
8	1/10	0/10	3/10	0/10
3-Week follow up	-	0/10	-	3-5*/10

NRS = Numeric Rating Scale (0 = no pain, 10 = worst imaginable pain). Pain was assessed immediately before and after each treatment session. Follow-up assessment of the left foot remained pain-free.

*Right foot pain at follow-up varied according to daily occupational workload.

Table 3. Patient-Specific Functional Scale (PSFS) outcomes

Outcome	Baseline	After Final Treatment	3 – Week Follow up
Standing At work	2/10	8/10	8/10
Walking after work	3/10	8/10	8/10

PSFS = Patient-Specific Functional Scale (0 = unable to perform the activity; 10 = able to perform the activity at the pre-condition level). Functional activities were selected by the patient based on her principal occupational limitations.

4. Discussion

4.1 Clinical interpretation

This case describes a 55-year-old woman with persistent bilateral plantar foot pain, clinically diagnosed as metatarsalgia in the left foot and plantar fasciitis in the right foot. Both conditions are commonly associated with mechanical loading, which was clinically relevant because the patient worked more than 50 hours per week in an upright position. Previous conservative interventions, including SWT and TECAR treatment, did not produce meaningful improvement, and pain remained high before EA was introduced. Both pain and patient-specific function improved markedly across the treatment period and were largely maintained at follow-up. However, the response was not equal in both feet. The sustained pain-free status of the left foot suggests a stronger response in metatarsalgia-related symptoms, whereas the persistence of workload-dependent right heel pain indicates that ongoing mechanical loading probably continued to influence the plantar fasciitis symptoms. Therefore, the clinical response should be interpreted as partial and activity-dependent rather than as complete resolution of both conditions.

4.2 Relation to existing literature

Current evidence supports conservative management for metatarsalgia and plantar fasciitis, including mechanical offloading, exercise, orthoses, footwear modification, SWT, and patient education[1–4,6]. These approaches are consistent with the mechanical nature of both conditions. In the present case, previous SWT and TECAR treatment did not reduce symptoms, which led to EA being used as an alternative pain-management approach.

Evidence for acupuncture and EA in foot and ankle pain is emerging, but it remains more developed for plantar heel pain than for metatarsalgia. A systematic review reported potential benefits of acupuncture for foot and ankle pain, while a randomized controlled trial comparing EA with manual acupuncture in plantar heel pain syndrome showed improvement in both groups over time[24,25]. However, evidence specifically supporting EA for metatarsalgia remains limited. Therefore, this case cannot establish treatment efficacy, but it may contribute clinically relevant information about the use of EA when standard conservative treatment has not produced sufficient improvement.

Consistent with the frequency-dependent opioid mechanisms[7,11], the initial mixed 2/100 Hz and later continuous 100 Hz stimulation were selected to provide an analgesic stimulus while adapting to the patient's tolerance. Experimental evidence also suggests that EA may attenuate pro-inflammatory cytokine activity[11,12]. As both conditions may involve a local inflammatory component, although chronic plantar fasciitis is often predominantly degenerative rather than inflammatory, an anti-inflammatory effect could hypothetically complement the opioid-mediated analgesia. However, this mechanism was not directly assessed in the present case[11].

4.3 Rationale and clinical reasoning for protocol adaptation

The protocol was adapted through iterative physiotherapy clinical reasoning, considering the patient's impairments, activity limitations, and contextual factors, consistent with the principles

of the International Classification of Functioning, Disability and Health (ICF). Persistent plantar pain represented the principal impairment, while prolonged standing and walking were the main activity limitations; occupational loading and poor tolerance of plantar needling were relevant contextual factors. When plantar needling proved intolerable, the intervention was re-evaluated to preserve the therapeutic objective while improving treatment tolerability. The therapeutic aim of stimulating the symptomatic plantar region was retained, but plantar needles were replaced with surface electrodes, and a single needle was maintained on the dorsum of the foot between the first and second metatarsals.

The adhesive surface electrode provides a larger conductive area than an acupuncture needle and may produce a broader electrical field than conventional needle-to-needle stimulation[14,15]. From the second session, the alternating 2/100 Hz waveform was replaced with continuous 100 Hz to further improve tolerance, with intensity titrated to comfort. Continuous-wave stimulation has been reported to produce a more stable EA sensation than alternating waveforms, although it habituates more readily[7,26].

The principal clinical relevance of this case lies in this treatment adaptation. The plantar surface is among the most sensitive sites for needling, and intolerance is a common reason patients decline or discontinue treatment. Retaining a single needle at a non-plantar point (LR3) while delivering stimulation to the sole through a surface electrode allowed the therapeutic current to be maintained while avoiding further painful plantar needle insertion.

The mechanistic basis remains inferential and should not be overstated. High-frequency stimulation has a plausible analgesic rationale mainly through dynorphin-mediated pathways[7,8,11], but this was supportive rather than the reason for the change, and direct evidence for continuous 100 Hz stimulation in plantar fasciitis is lacking. The change to continuous stimulation should therefore be regarded as an individualised, tolerance-driven adaptation rather than an established evidence-based protocol.

In addition to the characteristics of the needle–surface configuration, the selection of the needle site may also be relevant. LR3 was selected primarily for its anatomical proximity to the symptomatic region and its suitability as a well-tolerated dorsal needle site, allowing stimulation of the opposing plantar region. However, its selection may also have neurophysiological relevance, as experimental evidence suggests that acupuncture-point regions have been associated with increased concentrations of peripheral sensory nerve endings[27], while LR3 has also been identified within a mechanistically informed acupoint cluster associated with pain modulation and central neuromodulatory effects[28].

4.4 Strengths

The main strength of this case is the detailed description of the EA protocol, including needle type, electrode type, stimulation frequency, treatment duration, session number, and protocol modifications. Another strength is that the intervention was adapted according to patient tolerance, which reflects real clinical decision-making. The inclusion of repeated NRS measurements, PSFS outcomes, and a three-week follow-up adds clinically useful information about both pain intensity and patient-specific functional change.

This case also highlights a practical treatment adaptation for patients who poorly tolerate plantar needling. In sensitive plantar tissues, replacing some needle electrodes with adhesive patch electrodes may improve comfort while allowing electrical stimulation of the symptomatic region to continue.

4.5 Limitations

This case has several limitations. First, it is a single case report, so the findings cannot be generalized. Second, there was no control group; therefore, placebo effects, natural symptom fluctuation, regression to the mean, or delayed effects from previous treatments cannot be excluded. Third, the diagnoses were made clinically, and no imaging was obtained, limiting diagnostic certainty and preventing exclusion of other causes of plantar foot pain.

Pain was assessed using NRS, which is subjective, and manual palpation may introduce examiner bias. Although PSFS was included, only two functional activities were assessed. In addition, the treatment protocol changed during the course of care, making it impossible to determine whether the observed improvement was due to EA itself, the adhesive patch electrodes, the change to continuous 100 Hz, the reduced number of needles, or the combined effect of these factors. Finally, follow-up was limited to three weeks, and the intended course was shortened when the patient chose to stop after eight of ten sessions because her symptoms had improved.

4.6 Future directions

Future studies should compare needle–surface EA with needle-only EA, surface stimulation, and standard conservative care, while evaluating different stimulation frequencies, longer-term outcomes, and validated objective measures (e.g., Foot Function Index, Foot and Ankle Ability Measure, plantar pressure analysis, and ultrasound assessment of plantar fascia thickness) to determine whether improvements extend beyond short-term analgesia to functional and structural recovery.

5. Conclusion

This case suggests that needle–surface EA may be a useful clinical adaptation for patients with plantar foot pain who cannot tolerate plantar needling. The protocol modification reduced the need for needle insertion while maintaining electrical stimulation of the symptomatic region. Pain intensity and patient-specific function improved during the treatment period, with complete immediate post-treatment pain relief in both feet after the final session.

At the three-week follow-up, the left foot remained pain-free, while the right foot showed persistent activity-related pain, indicating a partial and workload-dependent response. The change to continuous 100 Hz stimulation was clinically driven and supported indirectly by frequency-dependent EA analgesia literature. However, direct evidence for continuous 100 Hz EA in plantar fasciitis and metatarsalgia remains limited. Therefore, this case should be interpreted as a clinically relevant example of individualised protocol adaptation rather than proof of treatment efficacy.

6. Patient Perspective

The patient reported the following: I was very frustrated by the persistent pain that limited my daily activities. I decided to try EA after other approaches had not provided relief. The first session was painful and almost brought me to the point of discontinuing the treatment. However, after discussing my concerns, the therapist modified the treatment approach. This proved much more comfortable and allowed me to return to my daily activities with far less pain.

References

1. Besse JL. Metatarsalgia. *Orthopaedics & Traumatology: Surgery & Research*. 2017;103(1): S29–S39. https://doi.org/10.1016/j.otsr.2016.06.020.

2. Ruiz-Ramos M, Orejana-García ÁM, García-Oreja S, Calvo-Wright M del M, Lázaro-Martínez JL, Molines-Barroso RJ. Effectiveness of bespoke or customised orthotic treatment in plantar pressure reduction of the central metatarsals: A systematic review and meta-analysis. *Journal of Orthopaedics*. 2025;59: 111–118. https://doi.org/10.1016/j.jor.2023.12.006.

3. Arias-Martín I, Reina-Bueno M, Munuera-Martínez P V. Effectiveness of custom-made foot orthoses for treating forefoot pain: a systematic review. *International Orthopaedics*. 2018;42(8): 1865–1875. https://doi.org/10.1007/s00264-018-3817-y.

4. Koc TA, Bise CG, Neville C, Carreira D, Martin RL, McDonough CM. Heel Pain – Plantar Fasciitis: Revision 2023. *Journal of Orthopaedic & Sports Physical Therapy*. 2023;53(12): CPG1–CPG39. https://doi.org/10.2519/jospt.2023.0303.

5. Liu P, Chen Q, Yang K, Cai F. Prevalence, characteristics, and associated risk factors of plantar heel pain in americans : The cross-sectional NHANES study. *Journal of Orthopaedic Surgery and Research*. 2024;19(1): 805. https://doi.org/10.1186/s13018-024-05300-y.

6. Morrissey D, Cotchett M, Said J'Bari A, Prior T, Griffiths IB, Rathleff MS, et al. Management of plantar heel pain: a best practice guide informed by a systematic review, expert clinical reasoning and patient values. *British Journal of Sports Medicine*. 2021;55(19): 1106–1118. https://doi.org/10.1136/bjsports-2019-101970.

7. Chen P, Xu H, Zhang R, Tian X song. Dose-effect relationship between electroacupuncture with different parameters and the regulation of endogenous opioid peptide system. *World Journal of Acupuncture - Moxibustion*. 2023;34(1): 9–15. https://doi.org/10.1016/j.wjam.2023.06.003.

8. Han JS. Acupuncture and endorphins. *Neuroscience Letters*. 2004;361(1–3): 258–261. https://doi.org/10.1016/j.neulet.2003.12.019.

9. Chao L, Gonçalves ASR, Campos ACP, Assis D V., Jerônimo R, Kuroki MA, et al. Comparative effect of dense-and-disperse versus non-repetitive and non-sequential frequencies in electroacupuncture-induced analgesia in a rodent model of peripheral neuropathic pain. *Acupuncture in medicine : journal of the British Medical Acupuncture Society*. 2022;40(2): 169–177. https://doi.org/10.1177/09645284211055751.

10. Bian Z, Wang J, Fang F, Yu B, Shi Y, Wan Y, et al. Study protocol for a randomized trial comparing two electroacupuncture waveforms for different severity groups of Bell palsy. *Frontiers in Neurology*. 2024;15: 1471605. https://doi.org/10.3389/FNEUR.2024.1471605.

11. Fang K, Cheng W, Yu B. Effects of Electroacupuncture at Varied Frequencies on Analgesia and Mechanisms in Sciatic Nerve Cuffing-Induced Neuropathic Pain Mice. *Journal of Molecular Neuroscience*. 2024;74(4): 98. https://doi.org/10.1007/s12031-024-02276-6.

12. Kim HW, Roh DH, Yoon SY, Kang SY, Kwon YB, Han HJ, et al. The Anti-Inflammatory Effects of Low- and High-Frequency Electroacupuncture Are Mediated by Peripheral Opioids in a Mouse Air Pouch Inflammation Model. *The Journal of Alternative and Complementary Medicine*. 2006;12(1): 39–44. https://doi.org/10.1089/acm.2006.12.39.

13. Cui H, Yu H, Huang X, Wu L, Zhong W, Gou Y, et al. Electroacupuncture and Transcutaneous Electrical Nerve Stimulation Induced Sensations in Bell's Palsy Patients: A Quantitative Current Intensity Analysis. *Frontiers in Neuroscience*. 2021;15. https://doi.org/10.3389/fnins.2021.692088.

14. Silva ML, Silva JR, Prado WA. The antinociceptive effect of electroacupuncture at different depths of acupoints and under the needling surface. *Chinese Medicine*. 2012;7(1): 3. https://doi.org/10.1186/1749-8546-7-3.

15. McIntyre CC, Grill WM. Finite Element Analysis of the Current-Density and Electric Field Generated by Metal Microelectrodes. *Annals of Biomedical Engineering*. 2001;29(3): 227–235. https://doi.org/10.1114/1.1352640.

16. Sha N, Kenney LPJ, Heller BW, Barker AT, Howard D, Moatamedi M. A Finite Element Model to Identify Electrode Influence on Current Distribution in the Skin. *Artificial Organs*. 2008;32(8): 639–643. https://doi.org/10.1111/j.1525-1594.2008.00615.x.

17. Naqvi WM, Mishra G V, Shaikh SZ, Pashine AA, Sánchez Romero EA, Swaminathan N, et al. PhyCARE reporting guidelines for physiotherapy case reports: a consensus-based development. *BMJ Open*. 2026;16(1): e110765. https://doi.org/10.1136/bmjopen-2025-110765.

18. Treede RD, Rief W, Barke A, Aziz Q, Bennett MI, Benoliel R, et al. Chronic pain as a symptom or a disease: the IASP Classification of Chronic Pain for the International Classification of Diseases (ICD-11). *Pain*. 2019;160(1): 19–27. https://doi.org/10.1097/j.pain.0000000000001384.

19. Pantheon Research. *Technical Info - Features Comparison*. https://pantheonresearch.com/pages/technical-info#explore [Accessed 18th July 2026].

20. World Health Organisation (WHO). *WHO standard acupuncture point locations in the Western Pacific region*. 2009. https://iris.who.int/handle/10665/353407 [Accessed 18th July 2026].

21. U.S. Food and Drug Administration (FDA). *Pantheon Electrostimulator Models 4c.Pro, 6c.Pro, 8c.Pro, 12c.Pro, 9c3i*. 2014. https://www.accessdata.fda.gov/cdrh_docs/pdf13/K133980.pdf [Accessed 10th August 2026].

22. Westaway MD, Stratford PW, Binkley JM. The Patient-Specific Functional Scale: Validation of Its Use in Persons With Neck Dysfunction. *Journal of Orthopaedic & Sports Physical Therapy*. 1998;27(5): 331–338. https://doi.org/10.2519/jospt.1998.27.5.331.

23. Bird SB, Dickson EW. Clinically significant changes in pain along the visual analog scale. *Annals of Emergency Medicine*. 2001;38(6): 639–643. https://doi.org/10.1067/mem.2001.118012.

24. Wang W, Liu Y, Jiao R, Liu S, Zhao J, Liu Z. Comparison of electroacupuncture and manual acupuncture for patients with plantar heel pain syndrome: a randomized controlled trial. *Acupuncture in Medicine*. 2021;39(4): 272–282. https://doi.org/10.1177/0964528420947739.

25. Trinh K, Belski N, Zhou F, Kuhad A, Luk D, Youn E. The Efficacy of Acupuncture on Foot and Ankle for Pain Intensity, Functional Status, and General Quality of Life in Adults: A Systematic Review. *Medical Acupuncture*. 2021;33(6): 386–395. https://doi.org/10.1089/acu.2021.0006.

26. Xuan C, Xiaoran Y, Suying G, Zhifang Y, Xiaoqing H. Frequency steps and compositions determine properties of needling sensation during electroacupuncture. *Journal of Traditional Chinese Medicine*. 2015;35(2): 154–159. https://doi.org/10.1016/S0254-6272(15)30022-4.

27. Li AH, Zhang JM, Xie YK. Human acupuncture points mapped in rats are associated with excitable muscle/skin–nerve complexes with enriched nerve endings. *Brain Research*. 2004;1012(1–2): 154–159. https://doi.org/10.1016/j.brainres.2004.04.009.

28. Karavis Y, Karavis M. Most Useful Acupuncture Points (MUAPs) Teaching Cluster: A Structured Narrative Review of Mechanistic Evidence for Biomedical Acupuncture Training. *Cureus.* 18(4): e106511. https://doi.org/10.7759/cureus.106511.

Editorial information

Correspondence

info@healthandresilience.org

Dates

Received: 19.07.2026
Accepted: 03.09.2026
Published: 16.09.2026

Author Contributions

Conceptualization, G.T.; methodology, G.T. and K.S.; validation, G.T. and K.S.; formal analysis, G.T. and N.G.; investigation, N.G.; resources, G.T.; data curation, N.G.; writing—original draft preparation, N.G. and G.T.; writing—review and editing, G.T. and K.S.; visualization, G.T.; supervision, G.T.; project administration, G.T. All authors have read and agreed to the published version of the manuscript.

Funding

This research received no external funding.

Ethics Statement

Formal ethics committee approval was not obtained for this single-patient case report, as the intervention was provided as part of routine clinical care and no experimental procedures were undertaken. Written informed consent was obtained from the patient for treatment and for publication of the clinical information presented in this case report. All identifying information has been withheld to protect the patient's privacy.

Data Availability Statement

All relevant data supporting the findings of this case report are included within the article. Additional anonymised data may be made available by the corresponding author upon reasonable request, subject to patient confidentiality.

Conflicts of Interest

N.G., K.S., and G.T. each declare no conflict of interest. No author has any financial or personal relationship with Pantheon Research Inc., Synergi Europe Ltd., or Globus Inc., whose products were used as standard commercially available equipment. These companies had no role in the study or the decision to publish.

Study Registration

This case report was not prospectively registered, as it describes the clinical management of a single patient and was not conducted as a prospective clinical study or trial.

Suggested citation

Ghines N, Simati K, Tzigkounakis G. Needle–Surface Electroacupuncture for Metatarsalgia and Plantar Fasciitis: A Clinical Case Report. Invasive Physiother Musculoskelet Med. 2026;2:e52. doi: 10.63360/ipmm.v2.e52

Disclaimer/Publisher's Note

The statements, opinions, and data contained in all publications are solely those of the individual author(s) and contributor(s) and not of IPMM and/or the editor(s). IPMM and/or the editor(s) disclaim responsibility for any injury to people or property resulting from any ideas, methods, instructions, or products referred to in the content.

Copyright
© 2026 by the authors.
Publication under the terms and conditions of the Creative Commons Attribution-NonCommercial-ShareAlike 4.0 International (CC BY-NC-SA) license (https://creativecommons.org/licenses/by-nc-sa/4.0)

Appendix

PhyCARE Reporting Checklist

Needle–Surface Electroacupuncture for Metatarsalgia and Plantar Fasciitis: A Clinical Case Report

Ghines N, Simati K, Tzigkounakis G.

Reporting guideline: Naqvi WM, Mishra GV, Shaikh SZ, et al. PhyCARE reporting guidelines for physiotherapy case reports: a consensus-based development. BMJ Open. 2026;16(1):e110765. doi:10.1136/bmjopen-2025-110765. The guideline comprises 35 items across 13 domains.

Item	Domain	Checklist item (summary)	Reported	Location in manuscript
1	Title	Identifies the report as a physiotherapy case report and names the condition(s) and the key intervention.	Yes	Title
2	Key words	Two to five key words capturing the condition and the physiotherapy intervention.	Yes	Keywords
3a	Abstract	Background – what is unusual about the case and why it is reported.	Yes	Abstract (Introduction)
3b		Main symptoms and important clinical findings.	Yes	Abstract (Case presentation)
3c		Primary diagnoses and therapeutic interventions.	Yes	Abstract (Case presentation)
3d		Main outcomes.	Yes	Abstract (Results)
3e		Concluding statement.	Yes	Abstract (Conclusions)
4	Introduction	Background, rationale and study objective, supported by references.	Yes	§1 Introduction
5a	Patient information	De-identified demographic and relevant baseline characteristics.	Yes	§2.1
5b		Main concerns and presenting symptoms.	Yes	§2.1–2.2
5c		Relevant medical, family, occupational and psychosocial/lifestyle history.	Yes	§2.1
5d		Relevant past interventions and their outcomes.	Yes	§2.1
6a	Clinical findings	Relevant physical examination and clinical findings.	Yes	§2.2
6b		Physiotherapy-specific assessments and standardized tests/outcome measures (distinguishing diagnostic from outcome measures).	Yes	§2.2 (NRS, palpation); §2.5 (PSFS)
6c		Functioning described within the ICF (or similar) framework: impairments, activity limitations, participation restrictions.	Yes	§4.3 (ICF); §2.1–2.2
7a	Timeline	Chronological account of the historical and current episode.	Yes	§2.3; Table 1
7b		Key dates/intervals of assessment and intervention.	Yes	§2.3; Table 1
7c		Prior medical and physiotherapy events/milestones.	Yes	§2.3; Table 1
7d		Timeline presented as a figure or table where helpful.	Yes	Table 1
8a	Diagnostic assessment	Assessment methods (examination, tests, measures).	Yes	§2.4
8b		Diagnostic challenges or limitations.	Yes	§2.4 (clinical diagnosis only; no imaging)
8c		Diagnosis and differential diagnoses.	Yes	§2.4
8d		Diagnostic images with key features labelled/defined.	N/A	No imaging obtained (stated in §2.4)

Item	Domain	Checklist item (summary)	Reported	Location in manuscript
9	Therapeutic intervention	Type, delivery and dosage of the intervention (needle/electrode configuration, frequency, intensity, duration, sessions) and any changes to it.	Yes	§2.5
10a	Outcomes and Follow-up	Outcome measures/assessment tools and time points.	Yes	§2.5; Tables 2–3
10b		Important patient-centred and functional outcomes.	Yes	§3; Tables 2–3
10c		Intervention adherence and tolerability.	Yes	§2.5; §3; §4.3
10d		Adverse events (or their explicit absence).	Yes	§3 (no adverse effects)
11a	Discussion	Strengths and limitations of the case.	Yes	§4.4; §4.5
11b		Discussion of relevant medical/physiotherapy literature.	Yes	§4.2
11c		Clinical reasoning and rationale for the intervention/adaptation.	Yes	§4.3
11d		Main takeaway and conclusions drawn from the case.	Yes	§4.1; §4.6; §5
12a	Patient perspective	The patient's own experience of the episode and treatment.	Yes	§6
12b		Caregiver perspective, if the patient is a minor/elderly/incapacitated (optional).	N/A	Competent adult patient
13	Informed consent	Statement that informed consent was obtained from the patient.	Yes	Editorial information: Ethics statement

Notes. Item summaries above are paraphrased from the PhyCARE guideline for reference; authors should confirm exact wording against the official checklist (BMJ Open 2026;16[1]:e110765, online supplemental file 7). Items 8d (diagnostic images) and 12b (caregiver perspective) are marked Not Applicable: no imaging was obtained (a clinical-only diagnosis, discussed as a limitation in §2.4/§4.5), and the patient was a competent adult, so no caregiver perspective was required.