Invasive Physiotherapy and Musculoskeletal Medicine

eISSN: 3101-0105 invasivephysiotherapy.com

doi: 10.63360/ipmm.v1.e18

Case Series

Assessment of Myofascial Trigger Points with ultrasound: a methodology combining external vibration with Power Doppler Imaging and B-mode

Pablo Herrero[1,2] 0000-0002-9201-0120

Diego Lapuente-Hernández[1,2] 0000-0002-6506-6081

Teresa Blanco[3,4] 0000-0002-1831-3342

Roberto Casas[3,5] 0000-0001-5316-8171

Fermín Valera-Garrido[6,7,8] 0000-0002-8867-2519

Francisco Minaya-Muñoz[6,7] 0000-0002-6337-2501

José Gomes Monres[9] 0000-0003-1317-1274

Eva María Gómez-Trullén[2,10] 0000-0002-7876-4735

[1]Faculty of Health Sciences, Department of Physiatry and Nursing, University of Zaragoza, 50009, Zaragoza, Spain.

[2]iHealthy Research Group, IIS Aragon, University of Zaragoza, 50009, Zaragoza, Spain

[3]Howlab Research Group, Aragon Institute of Engineering Research, Universidad de Zaragoza, 50018 Zaragoza, Spain.

[4]Department of Design and Manufacturing Engineering, University of Zaragoza, Zaragoza, Spain.

[5]Department of Electronics and Communication Engineering, University of Zaragoza, Zaragoza, Spain.

[6]MVClinic Institute, 28600 Madrid, Spain.

[7]CEU San Pablo University, 28925 Madrid, Spain.

[8]Invasive Physiotherapy Department, Getafe C.F., 28903 Madrid, Spain.

[9]Clínica Fisiogyn, Goiânia, Brasil.

[10]Faculty of Medicine, Department of Physiatry and Nursing, University of Zaragoza, 50009, Zaragoza, Spain.

This work was supported by Aragon Regional Government by the Program for Research Groups under Grant T27_23R and B54_23R

ABSTRACT

Introduction: This case series explores a novel methodology for identifying myofascial trigger points (MTrPs) by integrating Doppler and B-mode ultrasound with externally applied vibratory stimulation. The study aims to address the current lack of accessible and objective tools for MTrP assessment in clinical settings.

Case presentation: Five participants were included: four healthy individuals and one post-stroke patient. A custom-designed vibration device was developed to apply mechanical stimulation to the gastrocnemius medialis muscle, while ultrasound imaging was collected using a standardized setup. To optimize vibration signal detection within muscle tissue, different configurations of the electrodes transmitting the vibration and the Doppler modes (Color Doppler and Power Doppler Imaging (PDI)) were tested.

Results: PDI demonstrated superior sensitivity to vibration-induced muscle responses compared to conventional Color Doppler. A consistent pattern was identified among healthy participants. This pattern consisted of well-de-

4.0 BY-NC-SA

Correspondence: pherrero@unizar.es

fined, non-vibratory zones surrounded by vibratory regions, corresponding to hypoechoic areas on B-mode ultrasound. These findings are suggestive of MTrPs and distinct from other stiff anatomical structures, such as fascia, tendons, or fibrotic tissue, which appear hyperechoic. In the stroke patient, pathological muscle adaptations reduced the consistency and visibility of vibratory stimulus propagation; however, MTrP-compatible areas were still identified. Notably, dry needling altered the Doppler signal in this case, attenuating the previously observed pattern.

Conclusions: This proof-of-concept study demonstrates the feasibility and reproducibility of a cost-effective assessment protocol that uses conventional ultrasound modes. Combining PDI, B-mode, and vibration may improve the objective identification of MTrPs and expand capabilities in musculoskeletal practice.

Keywords: Myofascial trigger points; Diagnostic imaging; Doppler ultrasound; Vibration.

1. Introduction

The diagnosis of Myofascial Trigger Points (MTrPs) is a widely debated topic in the field of musculoskeletal medicine[1]. The lack of accessible, objective, and reproducible diagnostic tools continues to limit the diagnosis of MTrPs, which is usually made by palpation in clinical practice[2,3]. Despite the usefulness and accessibility of manual palpation, it depends mainly on the examiner's experience and cannot be used for the diagnosis of deep MTrPs[4,5]. To date, various studies have been published using advanced diagnostic techniques such as magnetic resonance imaging[6-8], electron microscopy[9], muscle biopsies[9-11], and elastography[12-16]. Due to their high cost, complexity, and limited availability, these techniques are not suitable for routine use in clinical practice.

In this context, musculoskeletal ultrasound has become a popular tool in rehabilitation, and it is being increasingly used in routine clinical practice. Its portability, low cost, and real-time capabilities for diagnostic and interventional procedures make it a promising technology[17,18]. However, its use to diagnose MTrPs is inconclusive due to the lack of standardized protocols and validated ultrasound diagnostic criteria[19,20]. If reliable results could be consistently obtained using the simplest and most accessible modes available in lower-end ultrasound devices, such as B-mode or Doppler mode, it could be immediately implemented in daily clinical practice and would have great potential for the diagnosis of MTrPs.

Several studies have shown that MTrPs are associated with biochemical, histopathological, and mechanical alterations, among others[21-23]. In the case of mechanical alterations, MTrPs have been shown to have increased tissue stiffness. Previous elastography studies, which assess tissue stiffness through its response to mechanical stimulation induced by a transducer or an external vibration source, have shown that stiff regions alter the propagation of mechanical waves, modifying the tissue's dynamic behavior and its representation in images[12-16]. Based on these findings, we propose a novel methodology combining the use of Doppler ultrasound simultaneously with an externally applied vibratory stimulation to muscle tissue, similar to the method used in previous research with sonoelastography[13,14,16].

The central hypothesis is that applying mechanical vibration to healthy muscle tissue will result in the propagation of a vibrational wave that generates a detectable Doppler signal. Conversely, regions with greater local stiffness, such as MTrPs, fibrosis, or intramuscular septa, may attenuate or block this mechanical transmission, resulting in the absence or focal reduction of the Doppler signal. If these phenomena, which have already been observed in elastography, could

be visualized using the conventional Doppler mode, this approach could be key for the objective assessment of MTrPs, allowing since this mode is included in the lower-end ultrasound devices. However, complementary criteria would need to be developed to distinguish MTrPs from other anatomical structures showing similar stiffness. Because of this, the combination of Doppler with other available modes, such as B-mode ultrasound, could improve identification using echointensity.

Although there is still controversy regarding the echogenicity of MTrPs, a recent review concluded that MTrPs were predominantly identified as hypoechoic nodules with heterogeneous echotexture[20]. Therefore, the use of B-mode ultrasound offers a unique opportunity to differentiate MTrPs from other structures when combined with Doppler ultrasound. The possibility of working with B-mode and Doppler mode in two windows simultaneously in many devices allows the clinician to identify stiffer areas in Doppler mode but showing a low echogenicity when compared with fascia or tendons. Therefore, the goal of this study is to lay the groundwork for a more accessible proof-of-concept methodology for identifying MTrPs using a combination of the most basic modes of musculoskeletal ultrasound, which are Doppler and B-mode with an external vibration source. This study aims to demonstrate a proof-of-concept based on a case series format, applying this methodology as a reference for future research and methodological improvements in MTrP assessment, also identifying methodological limitations and suggesting directions for future research.

2. Description of the case series

2.1 Participants information

This study presents a case series to illustrate a novel methodological approach to identifying MTrPs. Following initial testing of this novel methodology with researchers in the iHealthy research group (https://ihealthy.es/), four healthy volunteers (participant #1: male, 61 years; participant #2: male, 27 years; participant #3: male, 25 years; participant #4: female, 25 years) were recruited to illustrate the variability in findings across individuals. Furthermore, one participant with a stroke (participant #5: male, 75 years) was included to explore both the applicability and the potential challenges of transferring this methodology to clinical populations characterized by increased muscle stiffness and spasticity.

The study adhered to the ethical principles of the Declaration of Helsinki and received approval from the Aragon Ethics Committee (Reference: C.I. PI24/215, 13 May 2024). All participants were fully informed about all aspects related to the study in advance and provided written informed consent.

2.2 Vibration device

Initial pilot tests were performed using tuning forks to assess the feasibility of inducing muscle vibration detectable by Doppler ultrasound. However, significant limitations were encountered: the vibration was not homogeneously transmitted across the target region, and its duration was too brief to allow for scanning of the area. These constraints prompted the development of an *ad hoc* vibration device, custom-designed specifically for this study (Figure 1).



Figure 1. Final design of the vibration device.

A portable vibration device was developed following a user-centered design approach based on expert opinion from physiotherapy researchers. The initial user analysis revealed several key requirements: 1) the vibration must not generate discomfort to the patient, 2) vibration should be transmitted, allowing the physiotherapist to be hands-free to use the ultrasound and adjust the intensity of vibration, and 3) the vibration could not come into contact with the ultrasound transducer to avoid potential damage to the probe.

The development process began with a market analysis to identify existing solutions capable of inducing muscle vibration. Based on the findings, initial tests were conducted to assess vibratory wave propagation in muscle tissue. Prototypes were subsequently assembled using simple electronic components to test basic system functionality. Once operational, the design was refined in terms of ergonomics, functionality, and ease of use for clinical practitioners. Materials and manufacturing processes were selected to facilitate transformation into a final working prototype.

Two primary vibration sources were evaluated: sound wave-induced and mechanical motor-based vibration. The soundwave allows the finest tuning of the excitation source in terms of frequency and amplitude, but after a few tests, it was discarded due to the noise generated and the heating of the tissue. The final device was designed to operate under a mechanical motor-based vibration excited from 5 VDC (Direct Current Voltage) modulated using a PWM (pulse width modulation) signal. This allows for the graduation of power that energizes the eccentric motor in 10 vibration intensity levels. Vibration is transferred to the body using ECG patches (Dormo Ag/AgCl) clipped to the device; this ensures a tight connection, maximizing energy transfer from motor to tissue.

To further characterize the vibration profile of the device, an accelerometer with a 6.6 kHz sampling frequency was attached directly to the motor. The resulting measurements are presented in Table 1 and Figure 2.

Table 1. Frequency values recorded with the accelerometer at different vibration intensity levels of the device.

Vibration intensity	Frequency (Hz)
10%	303.00
20%	470.15
30%	602.95
40%	656.50
50%	701.68
60%	770.44
70%	801.92
80%	831.17
90%	883.25
100%	899.91

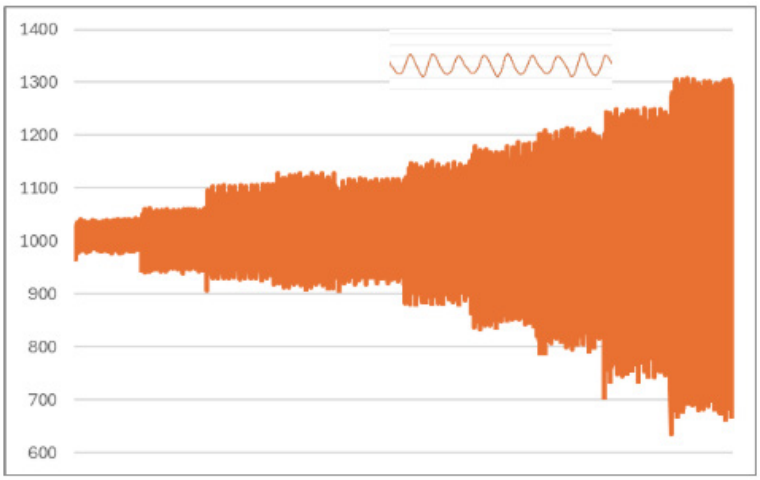

Figure 2. Time-domain accelerometer signal of the vibration device, showing the stability and reproducibility of the oscillatory pattern across intensity levels.

2.3 Data collection procedure

Ultrasound scanning was performed using a Sonophy Linear Wide Head probe, operating at a frequency range of 7.5–10 MHz (Sonophy, Spain). To ensure image standardization and minimize operator-dependent variability, a 190 cm Nineigh camera tripod was used to secure the probe in a fixed position throughout the examination, maintaining it perpendicular to the structure of interest. This setup avoided potential artefacts resulting from manual compression or probe movement, which could otherwise affect the Doppler signal. The muscle of interest selected was the gastrocnemius medialis, so the participant was positioned in lateral decubitus, with the examined limb placed in a neutral and relaxed position. Ultrasound gel was applied to facilitate acoustic coupling, and care was taken to avoid excessive probe pressure. The use of the tripod ensured both consistent probe angulation and reproducibility of imaging planes across different test conditions. The positioning of both the participant and the ultrasound probe using the tripod setup is illustrated in Figure 3.

Figure 3. Ultrasound probe positioning in transverse (Figure 3A) and longitudinal (Figure 3B) planes, stabilized with tripod support, with the participant lying in lateral decubitus.

To assess the viability of the proposed methodology for detecting MTrPs, a series of exploratory procedures was conducted. The influence of electrode positioning was evaluated using two configurations: 1) electrodes placed longitudinally on either side of the probe (Figure 4A); and 2) electrodes placed transversely across the probe width (Figure 4B). In both setups, Color Doppler and Power Doppler Imaging (PDI) modes were used sequentially to determine which modality best captured vibration-induced motion in muscle tissue.

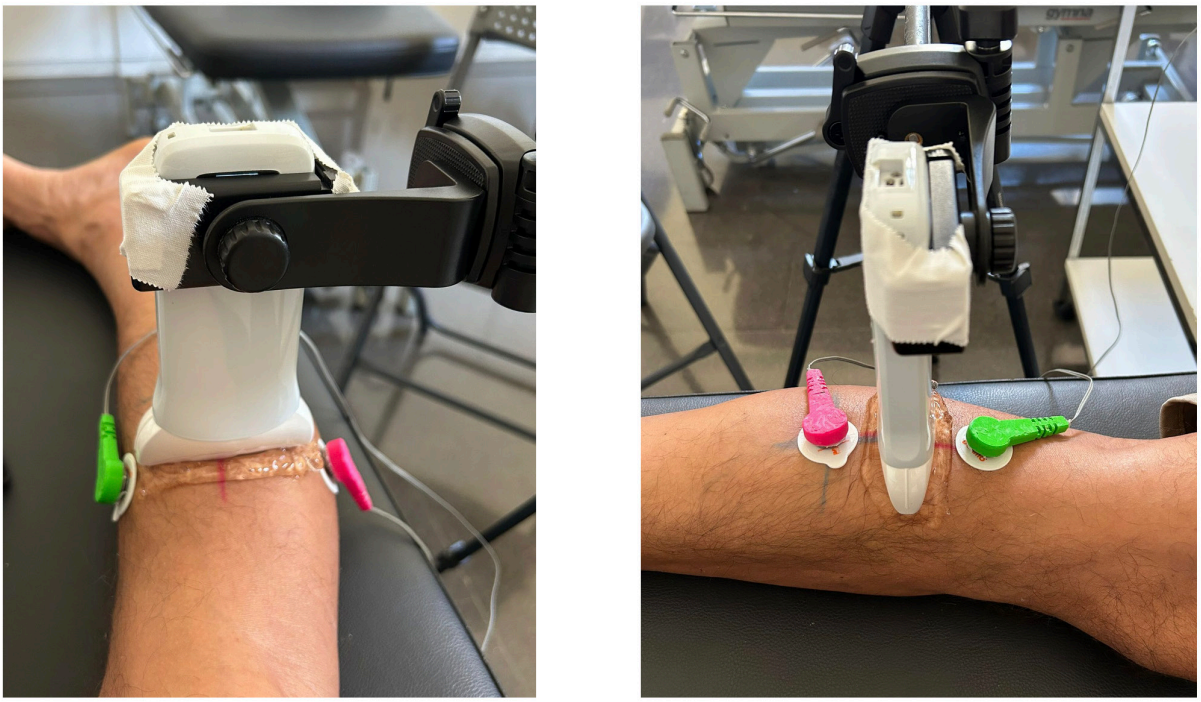

Figure 4. Ultrasound probe in transverse planes with electrodes placed longitudinally on each side (Figure 4A) and with electrodes aligned transversely along the probe width (Figure 4B).

Once the most effective method for transmitting vibration through the Doppler signal had been established, the next step was to determine the optimal evaluation protocol for identifying MTrP regions. Manual palpation was initially performed to palpate MTrPs in the gastrocnemius medialis muscle, following the most recent international consensus criteria published in 2018[24], after which the muscle was subsequently assessed using the proposed ultrasound methodology. An area within the same muscle without an MTrP served as the control site. For each examined region, repeated measurements were conducted by systematically removing and repositioning the ultrasound probe to assess intra-individual reproducibility. Throughout the process, multiple variations were explored to identify the configuration that yielded the most consistent and reliable imaging findings across repeated trials.

3. Results

To systematically compare the different protocols and set-ups, the vibratory response was assessed under both Color Doppler and PDI modes across multiple electrode arrangements, always using the maximum vibration intensity to ensure standardized evaluation conditions. Initial comparative testing revealed that transverse electrode positioning produced the most effective and homogeneous propagation of the vibratory stimulus through the muscle. This effect was particularly prominent in PDI mode, which outperformed Color Doppler mode in its ability to detect subtle differences in vibratory transmission. Videos S1-4 illustrate the comparative performance of each Doppler mode under different electrode placements.

To assess muscle tissue in both the transverse and longitudinal ultrasound planes, additional testing was conducted to determine if the vibratory stimulus could be consistently visualized in both orientations. We found that oblique electrode placement enabled seamless transitions between imaging planes, eliminating the need for electrode repositioning. This setup enabled vibration to propagate across the muscle belly in both orientations without signal loss. The quality and consistency of this setup are shown in Videos S5-6, and the corresponding electrode placements for each imaging plane are illustrated in Figure 5.

Once the optimal configuration was established (PDI mode with oblique electrode placement), the evaluation protocol was defined. During scanning, the vibration intensity was gradually increased until the entire PDI box, adjusted to its maximum size, showed uniform signal saturation. This confirmed that the vibratory stimulus had successfully propagated across the visible muscle area. The PDI box was then systematically moved throughout the imaging field to identify potential regions with a reduced vibratory response, which were hypothesized to represent areas of increased tissue stiffness. The proposed identifiable pattern was defined as a well-demarcated region lacking Doppler signal, surrounded by areas showing consistent vibratory activity. If the non-vibratory region appeared unstable or shifted position during scanning, this was interpreted as an artefact or inadequate transmission of the vibratory stimulus. The reproducibility of these findings was verified through repeated measurements in each site, with the probe removed and repositioned between acquisitions to confirm intra-individual consistency, as illustrated in Videos S7-8, which corresponds to the same MTrP region for the participant #1. Video S7 illustrates the first evaluation, while Video S8 shows the second assessment after the probe was removed and repositioned, demonstrating that the identified MTrP location remained unchanged.

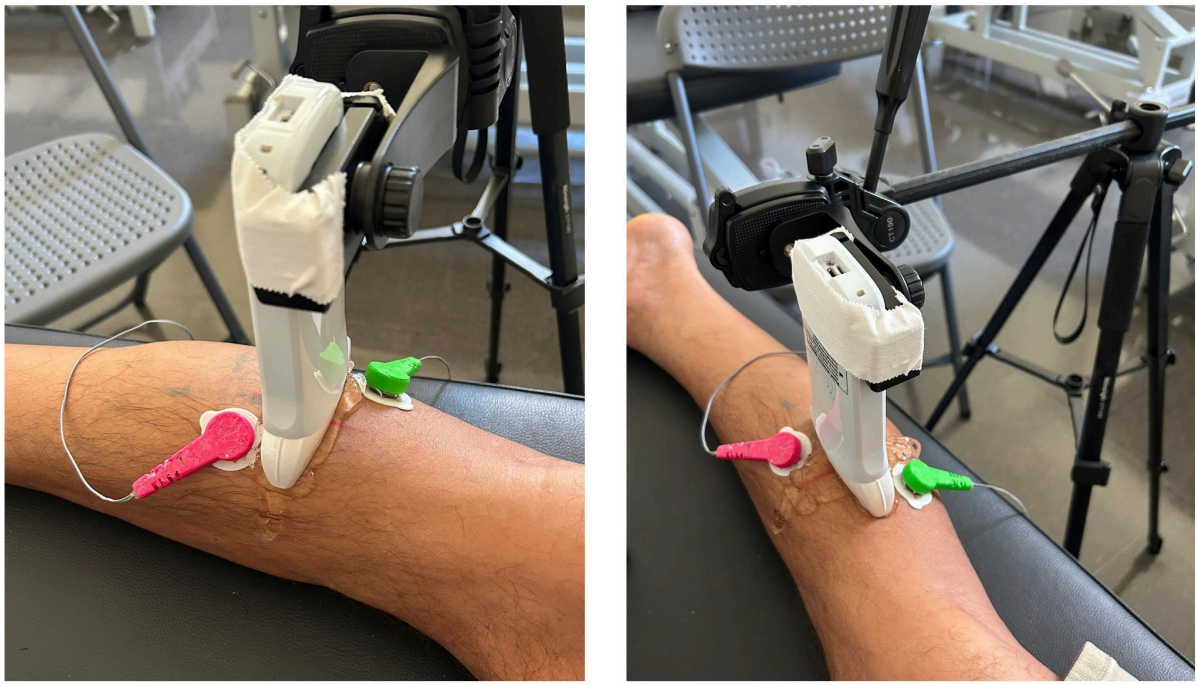

Figure 5. Oblique placement of electrodes with the ultrasound probe in transverse (Figure 5A) and longitudinal (Figure 5B) planes.

Videos S9-14 present representative examples of both suspected MTrP and non-MTrP regions under PDI mode in several healthy participants (Participants #2, #3, and #4). In all MTrP regions, at least one well-demarcated non-vibratory zone was consistently observed, which also corresponded to an area of lower echogenicity relative to the adjacent tissue. In contrast, non-MTrP regions showed no such characteristic non-vibratory pattern; instead, vibration was more homogeneously distributed across the muscle tissue.

In the participant with stroke (Participant #5), several difficulties were observed in transmitting the vibratory stimulus, which appeared unstable and failed to propagate homogeneously across the entire muscle belly, with extensive non-vibratory regions larger than those possibly associated with an MTrP, as illustrated in Video S15. This phenomenon may be attributable to increased muscle stiffness and the presence of fibro-adipose tissue. Nevertheless, in certain muscle regions, we were able to identify areas compatible with MTrPs, characterized by the pattern of a non-vibratory zone surrounded by adjacent regions with Doppler activity, although with less clarity due to the muscle tissue alterations (Video S16). Furthermore, in one of these MTrP regions, we tested the application of dry needling under PDI and vibration guidance. As shown in Video S17, after several needle insertions and subsequent removal, the Doppler activity within the previously non-vibratory region appeared to increase, and there was no such clear delineation.

Additionally, Videos S18-19 include representative images and videos showing the absence of a Doppler signal in regions with increased stiffness, such as superficial and deep fascial layers, in healthy volunteers. In all cases, these structures demonstrated the lack of a Doppler signal, further validating the method's ability to distinguish between tissues with different degrees of stiffness. B-mode was used as a complement to differentiate between physiological stiff tissue,

such as fascia, which appears as hyperechogenic structures, from stiffness potentially associated with MTrPs, which appears hypoechoic when compared with the aforementioned structures.

The vibration device did not result in any adverse events or side effects for any of the participants at any moment during the study, even when operated at maximum power.

4. Discussion

This study was designed as proof-of-concept based on a small number of cases. The primary objective was to investigate the feasibility of a novel assessment methodology for MTrPs and to explore any differences between musculoskeletal and neurological patients since both have MTrPs. Despite its exploratory nature, the consistency and reproducibility of the results provide a foundation to develop a standardized assessment approach in future research.

The proposed methodology uses a vibration source in combination with the PDI mode. However, one limitation in clinical practice for this methodology is that the vibration device used was specifically designed for this study, enabling precise adjustments to be made at very low intensity levels. Nevertheless, the ability to objectively identify MTrPs is a significant advance and opens up a potential avenue for future research. Specifically, confirming consistent characteristics in these non-vibratory zones, such as differences in echointensity or other echotexture features, could ultimately support the development of algorithms using B-mode imaging without vibration, which could be integrated directly into conventional ultrasound systems. Currently, however, B-mode ultrasound alone cannot reliably detect MTrPs due to the lack of validated diagnostic criteria, scarcity of quantitative assessments, subjectivity involved in interpreting grayscale images and limited interobserver reliability[20]. Future research should therefore focus on overcoming these limitations by using advanced image processing techniques and algorithmic approaches that can detect subtle variations in grayscale that are not distinguishable by the human eye with sufficient accuracy or consistency.

Unlike conventional Color Doppler ultrasound, PDI encodes the intensity of the Doppler signal rather than its velocity and direction. This feature makes PDI less dependent on the angle of the probe and substantially more sensitive to the detection of low-flow, small-calibre vessels[25-29]. Advantages include better delineation of tortuous vessels, greater definition of intravascular borders and superior visualization of vascular branches, which together provide a more contiguous vascular map[30]. These characteristics have established PDI as the method of choice for evaluating microvascularization in musculoskeletal conditions such as tendinopathy[27]. Although PDI has been used primarily to assess pathological vascularization in previous studies, the results are consistent with those observed in the context of our methodology, providing further evidence of the greater sensitivity and usefulness of PDI compared to Color Doppler. The main limitation of PDI compared to Color Doppler is that it cannot estimate the direction or velocity of flow[31]. However, this drawback does not affect its application in our methodology. Furthermore, previous research has demonstrated high intra-examiner consistency and reliability in different Doppler modes[32], which is consistent with our own observations, showing comparable results when probe repositioning was performed in the same participants.

Although the use of Color Doppler mode in the context of MTrPs has been previously investigated, demonstrating alterations in blood flow[14,33], this is the first study to utilize PDI mode to assess tissue stiffness, with the specific aim of identifying MTrPs using ultrasound. In this context, our methodology could provide a viable alternative for low- to mid-range ultrasound devices lacking elastography capabilities, thereby broadening the clinical application of MTrP assessment. The main limitation of this study is its proof-of-concept design, which was applied to a small number of cases. Additionally, the inclusion of a single stroke patient was intended solely as an exploratory example to assess potential feasibility in neurologically affected muscle, and no direct comparisons were made with healthy participants. Therefore, the results should be interpreted with caution and understood as a basis for future research.

Moreover, the ultrasound system used in this study limited the maximum size and shape of the Doppler box, which did not allow the use of a box that completely covered the gastrocnemius muscle section. This would have allowed simultaneous visualization of the MTrP and non-MTrP regions, facilitating interpretation and eliminating the need to move the box along the muscle in search of these non-vibratory areas. Future studies using more flexible Doppler settings could improve image coverage and pattern recognition. Although a tripod was used in this study to ensure probe stability and minimize Doppler signal artifacts, future research should evaluate whether handheld assessment, which is more consistent with daily clinical practice, can provide equally clear and reliable results. Finally, larger, well-controlled studies are required to rigorously evaluate the diagnostic accuracy, reliability, and potential clinical utility of this approach.

5. Conclusion

This proof-of-concept study introduces a novel methodology for identifying myofascial trigger points (MTrPs) using an external vibration source in conjunction with Power Doppler Imaging (PDI) and B-mode ultrasound. The approach yielded consistent and reproducible findings, suggesting that the absence of vibration-induced Doppler signal within an area that otherwise shows Doppler signal could serve as a reliable indicator of the greater stiffness characteristic of MTrPs.

Relying on conventional ultrasound modes available in most low- to mid-range devices, this methodology offers a feasible and low-cost option for clinical practice. The integration of Doppler and B-mode findings may facilitate the objective identification of MTrPs and contribute to more standardized assessment protocols in musculoskeletal medicine. While PDI makes it possible to identify the areas of increased stiffness, including both MTrPs, fascias, or fibrotic tissue, B-mode adds value by distinguishing hypoechoic MTrPs from hyperechoic fascia or fibrosis.

Supplementary materials

Video S1: Electrodes placed longitudinally - Color Doppler
Video S2: Electrodes placed longitudinally - Power Doppler Imaging
Video S3: Electrodes placed transversely - Color Doppler
Video S4: Electrodes placed transversely - Power Doppler Imaging
Video S5: Oblique electrode placement in transverse view - Power Doppler Imaging
Video S6: Oblique electrode placement in longitudinal view - Power Doppler Imaging
Video S7: Demonstration of the evaluation methodology in an MTrP region - first recording for participant #1
Video S8: Demonstration of the evaluation methodology in the same MTrP region - second recording for participant #1
Video S9: MTrP region in participant #2
Video S10: Non-MTrP region in participant #2
Video S11: MTrP region in participant #3
Video S12: Non-MTrP region in participant #3
Video S13: MTrP region in participant #4
Video S14: Non-MTrP region in participant #4
Video S15: Unstable vibration transmission in muscle tissue affected by stroke (participant #5)
Video S16: Example of an MTrP region in stroke (participant #5)
Video S17: Changes in Doppler activity after dry needling treatment in stroke (participant #5)
Video S18: Superficial fascia without Doppler activity
Video S19: Superficial and deep fascia without Doppler activity

References

1. Cook CE, Degenhardt B, Aspinall S, Nim C, Malik S, Keter D. Myofascial Pain Syndromes: Controversies and Suggestions for Improving Diagnosis and Treatment. J Orthop Sports Phys Ther. 2025;55. doi: 10.2519/jospt.2025.13072.

2. Steen JP, Jaiswal KS, Kumbhare D. Myofascial Pain Syndrome: An Update on Clinical Characteristics, Etiopathogenesis, Diagnosis, and Treatment. Muscle Nerve. 2025;71. doi: 10.1002/mus.28377.

3. Duarte FCK, West DWD, Linde LD, Hassan S, Kumbhare DA. Re-Examining Myofascial Pain Syndrome: Toward Biomarker Development and Mechanism-Based Diagnostic Criteria. Curr Rheumatol Rep. 2021;23. doi: 10.1007/s11926-021-01024-8.

4. Barbero M, Schneebeli A, Koetsier E, Maino P. Myofascial pain syndrome and trigger points: evaluation and treatment in patients with musculoskeletal pain. Curr Opin Support Palliat Care. 2019;13. doi: 10.1097/SPC.0000000000000445.

5. Myburgh C, Larsen AH, Hartvigsen J. A systematic, critical review of manual palpation for identifying myofascial trigger points: evidence and clinical significance. Arch Phys Med Rehabil. 2008;89. doi: 10.1016/j.apmr.2007.12.033.

6. Di Ieva A, Grizzi F, Rognone E, Tse ZT, Parittotokkaporn T, Rodriguez Y Baena F, Tschabitscher M, Matula C, Trattnig S, Rodriguez Y Baena R. Magnetic resonance elastography: a general overview of its current and future applications in brain imaging. Neurosurg Rev. 2010;33. doi: 10.1007/s10143-010-0249-6.

7. Landgraf MN, Ertl-Wagner B, Koerte IK, Thienel J, Langhagen T, Straube A, von Kries R, Reilich P, Pomschar A, Heinen F. Alterations in the trapezius muscle in young patients with migraine--a pilot case series with MRI. Eur J Paediatr Neurol. 2015;19. doi: 10.1016/j.ejpn.2014.12.021.

8. Sollmann N, Mathonia N, Weidlich D, Bonfert M, Schroeder SA, Badura KA, Renner T, Trepte-Freisleder F, Ganter C, Krieg SM, Zimmer C, Rummeny EJ, Karampinos DC, Baum T, Landgraf MN, Heinen F. Quantitative magnetic resonance imaging of the upper trapezius muscles - assessment of myofascial trigger points in patients with migraine. J Headache Pain. 2019;20. doi: 10.1186/s10194-019-0960-9.

9. Gerwin RD, Cagnie B, Petrovic M, Van Dorpe J, Calders P, De Meulemeester K. Foci of Segmentally Contracted Sarcomeres in Trapezius Muscle Biopsy Specimens in Myalgic and Nonmyalgic Human Subjects: Preliminary Results. Pain Med. 2020;21. doi: 10.1093/pm/pnaa019.

10. Jin F, Guo Y, Wang Z, Badughaish A, Pan X, Zhang L, Qi F. The pathophysiological nature of sarcomeres in trigger points in patients with myofascial pain syndrome: A preliminary study. Eur J Pain. 2020;24. doi: 10.1002/ejp.1647.

11. Shah JP, Phillips TM, Danoff JV, Gerber LH. An in vivo microanalytical technique for measuring the local biochemical milieu of human skeletal muscle. J Appl Physiol (1985). 2005;99. doi: 10.1152/japplphysiol.00419.2005.

12. Sikdar S, Shah JP, Gilliams E, Gebreab T, Gerber LH. Assessment of myofascial trigger points (MTrPs): a new application of ultrasound imaging and vibration sonoelastography. Annu Int Conf IEEE Eng Med Biol Soc. 2008;2008. doi: 10.1109/IEMBS.2008.4650480.

13. Sikdar S, Shah JP, Gebreab T, Yen RH, Gilliams E, Danoff J, Gerber LH. Novel applications of ultrasound technology to visualize and characterize myofascial trigger points and surrounding soft tissue. Arch Phys Med Rehabil. 2009;90. doi: 10.1016/j.apmr.2009.04.015

14. Ballyns JJ, Shah JP, Hammond J, Gebreab T, Gerber LH, Sikdar S. Objective sonographic measures for characterizing myofascial trigger points associated with cervical pain. J Ultrasound Med. 2011;30. doi: 10.7863/jum.2011.30.10.1331.

15. Ballyns JJ, Turo D, Otto P, Shah JP, Hammond J, Gebreab T, Gerber LH, Sikdar S. Office-based elastographic technique for quantifying mechanical properties of skeletal muscle. J Ultrasound Med. 2012;31. doi: 10.7863/jum.2012.31.8.1209.

16. Turo D, Otto P, Shah JP, Heimur J, Gebreab T, Zaazhoa M, Armstrong K, Gerber LH, Sikdar S. Ultrasonic characterization of the upper trapezius muscle in patients with chronic neck pain. Ultrason Imaging. 2013;35. doi: 10.1177/0161734612472408.

17. Zhang M, Xie K. Advances in Musculoskeletal Ultrasound for Assistive Diagnosis in Pain Clinics. Pain Ther. 2025;14. doi: 10.1007/s40122-025-00721-x.

18. Srbely JZ, Kumbhare D, Grosman-Rimon L. A narrative review of new trends in the diagnosis of myofascial trigger points: diagnostic ultrasound imaging and biomarkers. J Can Chiropr Assoc. 2016;60. PMID: 27713577

19. Elbarbary M, Sgro A, Goldberg M, Tenenbaum H, Azarpazhooh A. Diagnostic Applications of Ultrasonography in Myofascial Trigger Points: A Scoping Review and Critical Appraisal of Literature. J Diagn Med Sonogr. 2022;38. doi:10.1177/87564793221102593.

20. Lapuente-Hernández D, Alboloushi Z, Aljobrani C, Herrero P, Gómez-Trullén EM. B-mode ultrasound characterization of myofascial trigger points and their response to physiotherapy interventions: a systematic review. Invasive Physiother Musculoskelet Med. 2025;1. doi: 10.63360/ipmm.v1.e3.

21. Shah JP, Gilliams EA. Uncovering the biochemical milieu of myofascial trigger points using in vivo microdialysis: an application of muscle pain concepts to myofascial pain syndrome. J Bodyw Mov Ther. 2008;12. doi: 10.1016/j.jbmt.2008.06.006.

22. Margalef R, Sisquella M, Bosque M, Romeu C, Mayoral O, Monterde S, Priego M, Guerra-Perez R, Ortiz N, Tomàs J, Santafe MM. Experimental myofascial trigger point creation in rodents. J Appl Physiol (1985). 2019;126. doi: 10.1152/japplphysiol.00248.2018.

23. Chen Q, Bensamoun S, Basford JR, Thompson JM, An KN. Identification and quantification of myofascial taut bands with magnetic resonance elastography. Arch Phys Med Rehabil. 2007;88. doi: 10.1016/j.apmr.2007.07.020.

24. Fernández-de-Las-Peñas C, Dommerholt J. International Consensus on Diagnostic Criteria and Clinical Considerations of Myofascial Trigger Points: A Delphi Study. Pain Med. 2018;19. doi: 10.1093/pm/pnx207.

25. Rubin JM, Bude RO, Carson PL, Bree RL, Adler RS. Power Doppler US: a potentially useful alternative to mean frequency-based color Doppler US. Radiology. 1994;190. doi: 10.1148/radiology.190.3.8115639.

26. Smith E, Azzopardi C, Thaker S, Botchu R, Gupta H. Power Doppler in musculoskeletal ultrasound: uses, pitfalls and principles to overcome its shortcomings. J Ultrasound. 2021;24. doi: 10.1007/s40477-020-00489-0.

27. Richards PJ, Win T, Jones PW. The distribution of microvascular response in Achilles tendonopathy assessed by colour and power Doppler. Skeletal Radiol. 2005;34. doi: 10.1007/s00256-004-0834-2.

28. Weskott HP. Amplitude Doppler US: slow blood flow detection tested with a flow phantom. Radiology. 1997;202. doi: 10.1148/radiology.202.1.8988201.

29. Yang X, Pugh ND, Coleman DP, Nokes LD. Are Doppler studies a useful method of assessing neovascularization in human Achilles tendinopathy? A systematic review and suggestions for optimizing machine settings. J Med Eng Technol. 2010;34. doi: 10.3109/03091902.2010.497892.

30. Martinoli C, Pretolesi F, Crespi G, Bianchi S, Gandolfo N, Valle M, Derchi LE. Power Doppler sonography: clinical applications. Eur J Radiol. 1998;27 Suppl 2. doi: 10.1016/s0720-048x(98)00054-0.

31. Hamper UM, DeJong MR, Caskey CI, Sheth S. Power Doppler imaging: clinical experience and correlation with color Doppler US and other imaging modalities. Radiographics. 1997;17. doi: 10.1148/radiographics.17.2.9084086.

32. Risch L, Cassel M, Messerschmidt J, et al. Is Sonographic Assessment of Intratendinous Blood Flow in Achilles Tendinopathy Patients Reliable?: Consistency of Doppler Ultrasound Modes and Intra- and Inter-observer Reliability. Ultrasound Int Open. 2016;2. doi:10.1055/s-0035-1569286.

33. Sikdar S, Ortiz R, Gebreab T, Gerber LH, Shah JP. Understanding the vascular environment of myofascial trigger points using ultrasonic imaging and computational modeling. Annu Int Conf IEEE Eng Med Biol Soc. 2010;2010. doi: 10.1109/IEMBS.2010.5626326.

Editorial information

Correspondence

pherrero@unizar.es

Dates

Received: 30.09.2025
Accepted: 10.11.2025
Published: 27.11.2025
Updated: 13.10.2026. Editorial handling statement added to Conflicts of Interest. No other changes.

Author Contributions

Conceptualization, P.H., D.L.H. and J.G.M.; methodology, P.H., D.L.H., T.B., R.C., F.V.G., F.M.M., J.G.M. and E.M.G.T.; vibration device, T.B. and R.C.; writing—original draft preparation, P.H. and D.L.H.; writing—review and editing, P.H., D.L.H., T.B., R.C., F.V.G., F.M.M., J.G.M. and E.M.G.T.; supervision, P.H., D.L.H. and E.M.G.T; funding acquisition, P.H., D.L.H. and E.M.G.T. All authors have read and agreed to the published version of the manuscript.

Funding

This study is funded by the Department of Education, Science and Universities of the Government of Aragon through Order CUS/621/2023, dated May 10, which calls for grants for the hiring of pre-doctoral research personnel in training for the period 2023-2027 (BOA 93 of 18 May 2023).

This work was supported by Aragon Regional Government by the Program for Research Groups under Grant T27_23R and B54_23R.

Acknowledgments

The authors would like to sincerely thank all participants for their valuable time, commitment, and collaboration throughout the study. We also gratefully acknowledge Andrés Rubio Palomar for his contribution to the development of the vibration device.

Patient's informed consent

Informed consent was obtained from all subjects involved in the study.

Data Availability Statement

The datasets generated during and/or analyzed during the current study are available from the corresponding author on reasonable request.

Conflicts of Interest

Pablo Herrero is Editor-in-Chief of IPMM. This manuscript was handled by another editor, and he was not involved in the peer review or the editorial decision. The other authors declare no conflicts of interest.

Suggested citation

Herrero P, Lapuente-Hernández D, Blanco T, Casas R, Valera-Garrido F, Minaya-Muñoz F, Gomes Monres J, Gómez-Trullén EM. Assessment of myofascial trigger points with ultrasound: a methodology combining external vibration with power Doppler imaging and B-mode. Invasive Physiother Musculoskelet Med. 2025;1:e18. doi: 10.63360/ipmm.v1.e18

Disclaimer/Publisher’s Note

The statements, opinions, and data contained in all publications are solely those of the individual author(s) and contributor(s) and not of IPMM and/or the editor(s). IPMM and/or the editor(s) disclaim responsibility for any injury to people or property resulting from any ideas, methods, instructions, or products referred to in the content.

Copyright

© 2025 by the authors.

Publication under the terms and conditions of the Creative Commons Attribution-NonCommercial-ShareAlike 4.0 International (CC BY-NC-SA) license

(https://creativecommons.org/licenses/by-nc-sa/4.0)